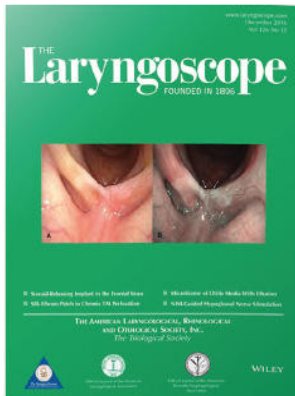



Premiere Publications from The Triological Society

Read all three of our prestigious publications, each offering high-quality content to keep you informed with the latest developments in the field.




THE Laryngoscope FOUNDED IN 1896

Editor-in-Chief: Michael G. Stewart, MD, MPH

The leading source for information in head and neck disorders.

Laryngoscope.com




Laryngoscope Investigative Otolaryngology Open Access

Editor-in-Chief: D. Bradley Welling, MD, PhD, FACS

Rapid dissemination of the science and practice of otolaryngology-head and neck surgery.

InvestigativeOto.com



ENTtoday A publication of the Triological Society



Editor-in-Chief: Alexander Chiu, MD

Must-have timely information that Otolaryngologist-head and neck surgeons can use in daily practice.

Enttoday.org

WILEY

Lingual Frenuloplasty With Myofunctional Therapy: Exploring Safety and Efficacy in 348 Cases

Soroush Zaghi, MD ; Sanda Valcu-Pinkerton, RDH-AP; Mia Jabara, BS; Leyli Norouz-Knutsen, BA; Chirag Govardhan, BS; Joy Moeller, RDH; Valerie Sinkus, PT; Rebecca S. Thorsen, MS, CCC-SLP; Virginia Downing, RDH; Macario Camacho, MD ; Audrey Yoon, DDS, MS; William M. Hang, DDS, MSD; Brian Hockel, DDS; Christian Guilleminault, DM, MD; Stanley Yung-Chuan Liu, MD, DDS

Background: Ankyloglossia is a condition of altered tongue mobility due to the presence of restrictive tissue between the undersurface of the tongue and the floor of mouth. Potential implications of restricted tongue mobility (such as mouth breathing, snoring, dental clenching, and myofascial tension) remain underappreciated due to limited peer-reviewed evidence. Here, we explore the safety and efficacy of lingual frenuloplasty and myofunctional therapy for the treatment of these conditions in a large and diverse cohort of patients with restricted tongue mobility.

Methods: Four hundred twenty consecutive patients (ages 29 months to 79 years) treated with myofunctional therapy and lingual frenuloplasty for indications of mouth breathing, snoring, dental clenching, and/or myofascial tension were surveyed. All procedures were performed by a single surgeon using a scissors and suture technique. Safety and efficacy was assessed >2 months postoperatively by means of patient-reported outcome measures.

Results: In all, 348 surveys (83% response rate) were completed showing 91% satisfaction rate and 87% rate of improvement in quality of life through amelioration of mouth breathing (78.4%), snoring (72.9%), clenching (91.0%), and/or myofascial tension (77.5%). Minor complications occurred in <5% of cases including complaints of prolonged pain or bleeding, temporary numbness of the tongue-tip, salivary gland issues, minor wound infection or inflammation, and need for revision to excise scar tissue. There were no major complications.

Conclusion: Lingual frenuloplasty with myofunctional therapy is safe and potentially effective for the treatment of mouth breathing, snoring, clenching, and myofascial tension in appropriately selected patient candidates. Further studies with objective measures are merited.

Key Words: Lingual frenuloplasty, tongue-tie, lingual frenum, frenectomy, ankyloglossia, myofunctional therapy, orofacial myology, tongue and orofacial exercises.



Level of Evidence: 3

A Special Visual Abstract has been developed for this paper


The visual abstract is a structured infographic with a blue and white color scheme. At the top left is the journal logo 'Laryngoscope Investigative Otolaryngology' with 'Open Access' below it. The main title 'Lingual Frenuloplasty with Myofunctional Therapy: Exploring Safety and Efficacy' is in a dark blue box. The content is organized into three columns: 1. 'ANKYLOGLOSSIA aka TONGUE TIE' with a diagram of a tongue tied to the floor of the mouth and text 'Restricted Tongue Mobility' and 'Breathing, Eating, Speaking, Muscle Tension Issues'. 2. 'INTERVENTION' with 'MYOFUNCTIONAL THERAPY (strengthen tongue)' and 'LINGUAL FRENULECTOMY' (Scissor and Suture Technique) accompanied by icons of a tongue and surgical tools. 3. 'OUTCOMES' with 'n = 348 (83% response rate)', 'Ages 29 months - 79 years', 'Patient Surveys' (91% Satisfaction, Improvement in: Mouth breathing: 78%, Muscle tension: 77%, Snoring: 73%, Clenching: 91%, Minor Complications: <5%), and 'CONCLUSION: Frenuloplasty + myofunctional therapy can be safe and effective'. At the bottom, author names and DOI '10.1002/liv.2.297' are listed, along with a credit to the creator.

Laryngoscope Investigative Otolaryngology
Open Access

Lingual Frenuloplasty with Myofunctional Therapy: Exploring Safety and Efficacy

ANKYLOGLOSSIA aka TONGUE TIE	INTERVENTION	OUTCOMES
<p>Restricted Tongue Mobility</p>  <p>Breathing, Eating, Speaking, Muscle Tension Issues</p>	<p>MYOFUNCTIONAL THERAPY (strengthen tongue)</p>  <p>- ≥ 1 month pre-op - ≥ 2 months post-op</p> <p>+</p> <p>LINGUAL FRENULECTOMY</p>  <p>Scissor and Suture Technique</p>	<p>n = 348 (83% response rate) - Ages 29 months - 79 years</p> <p>Patient Surveys</p> <ul style="list-style-type: none">- 91% Satisfaction- Improvement in:<ul style="list-style-type: none">* Mouth breathing: 78%* Muscle tension: 77%* Snoring: 73%* Clenching: 91%- Minor Complications: <5% <p>CONCLUSION</p> <p>Frenuloplasty + myofunctional therapy can be safe and effective</p>

Zaghi S, Valcu-Pinkerton S, Jabara M, Norouz-Knutsen L, Govardhan C, Moeller J, Sinkus V, Thorsen R, Downing V, Camacho M, Yoon A, Hang W, Hockel B, Guilleminault C, and Liu S
DOI: 10.1002/liv.2.297

#VisualAbstract created by Jennifer Villwock, MD
 @docwck

INTRODUCTION

Ankyloglossia is a condition of altered tongue mobility due to the presence of restrictive tissue between the undersurface of the tongue and the floor of mouth.¹ Restricted tongue mobility may be caused by a short mucosal lingual frenulum and/or by submucosal myofascial fibers of the underlying genioglossus muscle that are fibrosed and impair optimal oral functions.² Ankyloglossia may also be attributed to scar tissue from a prior surgical procedure or other trauma.

The un-tethered mobility of the tongue is required for optimal speech, chewing, swallow, oral hygiene, and breathing functions,³ as well as for development of the maxillofacial complex and upper airway.^{4,5} Because the tongue plays such an important role in so many functions, restricted mobility of the tongue muscle may lead to dysfunctional compensations that may negatively affect nasal breathing and snoring due to low tongue posture or contribute to chronic stress on the other muscles of the head and neck. The tongue is directly connected to the hyoid bone and has connections to the whole body (through the fascial diaphragms all the way down to the feet) through webs of connective tissue known as fascia.^{6,7} A restrictive tongue may place tension on the deep front line of fascia (among other connective tissue networks) and contribute to neck tension, pain, and postural dysfunction.⁸ As such, compensations for ankyloglossia may contribute to a wide variety of issues presenting as oromyofascial dysfunction.

Potential implications of restricted tongue mobility (such as mouth breathing, snoring, dental clenching, and myofascial tension) remain underappreciated due to limited peer-reviewed evidence.⁹ It is also worth mentioning the unfortunate lack of clinical studies pertaining to safety and efficacy of the various treatment modalities for ankyloglossia. While there are numerous methodologies that might be considered or applied for the treatment of ankyloglossia, the purpose of the present study was to explore the safety and efficacy of lingual frenuloplasty and myofunctional therapy in a large and diverse cohort of patients with restricted tongue mobility.

METHODS

Study Design

Retrospective cohort study involving 348 of 420 consecutive patients who were treated with lingual frenuloplasty

and myofunctional therapy. Presenting complaints included one or more of the following symptoms: mouth breathing ($n = 226$), snoring ($n = 151$), dysfunctional swallow pattern ($n = 130$), clenching ($n = 44$), and/or myofascial pain or tension ($n = 151$). All procedures were performed by a single surgeon (S.Z.). The study involved a retrospective chart review and telephone survey of patients treated between March 12, 2016, and May 2, 2018. Verbal informed consent was obtained to participate in the survey. The study was performed as part of Stanford University IRB Number 6208, Protocol # 36385 approved on January 25, 2016.

Inclusion and Exclusion Criteria

Patients older than 2 years of age were included. Patients who underwent other adjunctive surgical procedures (such as adenoidectomy, tonsillectomy, or nasal surgery) were excluded. Non-English speaking patients were also excluded. During the time period of the study, 446 patients in total underwent a lingual frenuloplasty in conjunction with myofunctional therapy, among whom 420 met the inclusion criteria for participation in the study. Myofunctional therapy was a prerequisite to surgery for all patients. This cohort study does not account for patients who were referred for myofunctional therapy but did not pursue or require surgical treatment.

Treatment Protocol—Myofunctional Therapy

Orofacial myofunctional therapy (also known as orofacial myology) has been used for many years to repattern maladaptive oral habits (such as prolonged thumb-sucking, nail biting, tongue thrusting, and open-mouth at rest posture) among other objectives.¹⁰ More recently, myofunctional therapy has been demonstrated as a potentially effective treatment option for sleep-disordered breathing.^{11–14} However, restricted tongue mobility may interfere with the goals and limit the efficacy of myofunctional therapy. Patients with ankyloglossia may experience difficulty protruding, lateralizing, and most importantly elevating the tip or body of the tongue. Such functional impairments in the mobility of the tongue may prove a barrier in achieving tongue-to-palate contact necessary to create the “suction-cup” effect that holds the tongue in place and prevents it from falling into the pharynx at rest.

Patients included in this series were required to complete at least 1 month of preoperative and encouraged

Additional supporting information may be found online in the Supporting Information section at the end of the article.

This is an open access article under the terms of the Creative Commons Attribution-NonCommercial-NoDerivs License, which permits use and distribution in any medium, provided the original work is properly cited, the use is non-commercial and no modifications or adaptations are made.

From the The Breathe Institute (S.Z., S.V.-P., M.J., L.N.-K., C.G., J.M., V.S., R.S.T., V.D.), Los Angeles, California, U.S.A.; UCLA Health (S.Z.), Santa Monica, California, U.S.A.; Academy of Orofacial Myofunctional Therapy (J.M.), Pacific Palisades, California, U.S.A.; Long Beach Speech Pathology (R.S.T.), Long Beach, California, U.S.A.; Orofacial Integrity (V.D.), Oakland, California, U.S.A.; Tripler Army Medical Center (M.C.), Honolulu, Hawaii, U.S.A.; Section of Pediatric Dentistry, Division of Growth and Development (A.Y.), UCLA School of Dentistry, Los Angeles, California, U.S.A.; Division of Sleep Surgery, Department of Otolaryngology-Head & Neck Surgery (A.Y., S.Y.-C.L.), Stanford University School of Medicine, Stanford, California, U.S.A.; William M Hang, DDS, MSD - A Prof Corp (W.M.H.), Agoura Hills, California, U.S.A.; Life Dental and Orthodontics (B.H.), Walnut Creek, California, U.S.A.; Department of Psychiatry, Sleep Medicine Division (C.G.), Stanford Hospital and Clinics, Redwood City, California, U.S.A.

Editor's Note: This Manuscript was accepted for publication on July 9, 2019

Conflict of Interest: The authors here report results on a surgical and myofunctional therapy technique for which they do not have any conflicts of interest outside of clinical practice, advocacy, and promotion of education in this field.

Funding Information: No sponsorship or external funding was used to support this study.

Disclaimer: For author Macario Camacho, it is noted that the views herein are the private views of the author and do not reflect the official views of the Department of the Army or the Department of Defense.

Send correspondence to Soroush Zaghi, MD, The Breathe Institute, 10921 Wilshire Blvd Suite 912, Los Angeles, CA 90024. Email: soroush.zaghi@gmail.com

DOI: 10.1002/lto.2.297

to follow-up with at least 2 months of postoperative myofunctional therapy. The goals of preoperative therapy are to create awareness of oral posture and tongue functions, strengthen and tone the muscles of the tongue and orofacial complex, and rehabilitate compensation patterns that may affect the postoperative recovery (e.g., floor of mouth elevation, muscular neck engagement, and inability to perform isolated movements with the tongue without moving the jaw). Postoperative myofunctional therapy for lingual frenuloplasty provides individualized care for the patient to optimize recovery and healing after surgery by providing guidance with passive and active wound stretching, as well as strength training and pattern retraining exercises for the tongue and orofacial muscles. Myofunctional therapy often continues for 1 year or longer to prevent relapse of dysfunctional oral motor habits, promote exclusive nasal breathing, and ensure long-term habituation of ideal resting oral posture. The myofunctional therapy protocol in this study was not standardized across patients and, in some cases, incorporated bodywork, cranio-sacral therapy, and/or myofascial therapy depending on the clinical circumstance. Proposed guidelines for collaboration between surgeons and therapists in the treatment of ankyloglossia among children and adults are given in Supporting Information.

Lingual Frenuloplasty with Scissors and Suture Technique

Lingual frenuloplasty helps to optimize the efficacy of myofunctional therapy by improving tongue mobility. Local anesthesia is achieved by applying topical viscous lidocaine followed by 0.5–1.7 cc of 1% lidocaine with 1:200,000 epinephrine to the lingual frenulum via a 27-gauge needle. The patient is instructed to open the mouth and hold the tip of the tongue to the incisive papilla behind the maxillary central incisors to reveal tension to the lingual frenulum band. Tension is applied to the floor of the mouth with a groove director so as to protect the floor of mouth salivary glands. A hemostat is used to clamp the restrictive lingual frenulum 2–5 mm above the attachments of the submandibular gland duct. The mucosal frenulum is gently excised with the use of 120 mm Baby Metzenbaum or Iris scissors (curved or straight tip). The median lingual septum (fascia between the two head of the superior branch of the genioglossus muscle) is identified and dissected. The underlying myofascial fibers of the genioglossus muscle are dissected further with a combination of blunt and sharp dissection. Sterilized blunt cotton-tips and manual palpation with 2 × 2 sterile cotton gauze are used for blunt dissection. The patient undergoes an assessment intraoperatively to determine the presence of residual restrictive muscle or fascia bands that are restrictive of tongue mobility. The dissection is continued until adequate improvement to tongue mobility is achieved: that is, tongue could be extended up toward the maxillary central incisors in maximal mouth opening position as well as held in lingual-palatal suction against the entire anterior and posterior aspects of the roof of the mouth without tension or strain. For cases performed under general anesthesia, a 2–0 silk suture is applied and

used to mobilize the tongue for similar movements. Simple interrupted 3–0 or 4–0 chromic sutures are used to close the diamond-shaped mucosal defect and promote healing by primary intention healing. There was no use of electrocautery, silver nitrate, or thermal ablation with laser in this scissors and suture technique for lingual frenuloplasty. Hemostasis was achieved with suture ligation techniques and/or application of 2 × 2 gauze until bleeding subsided. No antibiotics were prescribed or administered postoperatively. Patients were recommended oral rinses with salt water or nonalcoholic mouthwash three times daily for 1–2 weeks after the procedure; some patients also elected to use vitamin E oil or colloidal silver spray. Pain control regimen included application of topical 2% viscous lidocaine, ibuprofen, Tylenol, and/or narcotics such as tramadol, hydrocodone, or oxycodone (as needed for more severe pain). Some patients elected to use homeopathic (such as arnica) or holistic remedies (turmeric, ginger, and cannabidiol oil) for analgesia instead of the other more routine allopathic medications. Sutures usually fell out within 2–10 days. Gentle brushing of the wound after 5–7 days to debride granulation tissue with a soft surgical toothbrush (Curaprox C Surgical Mega Soft) was found to be helpful.

Survey

Surveys were conducted at least 2 months after the frenuloplasty procedure in a structured interview format incorporating dichotomous and open-ended questions via telephone. The following items were assessed: age, gender, tongue-tie severity, indication for lingual frenulum release, local or general anesthesia, duration of time to follow-up, benefits, and complications. Severity of pain and complications were graded on a 10-point visual analog scale. Changes to the overall health-related quality of life and overall satisfaction were assessed using a 5-point Likert scale. For prepubertal children, the survey was completed by the parents. Continuous variables are summarized as mean (M) ± standard deviation (SD). Categorical variables are summarized as frequencies and percentages ± standard error (SE), where applicable.

RESULTS

There were 348 surveys completed among 420 consecutive patients who were contacted (83% response rate). Subjects include 110 children (ages 2–11), 35 adolescents (age 12–17), 69 young adults (age 18–35), 120 adults (age 36–64), and 14 seniors (age ≥65). Gender distribution was 52.0% female. There were 63 children treated under general anesthesia; all other cases were performed under local anesthesia. The average duration of time from treatment date to follow-up was 4.3 ± 3 months, ranging from 2 to 20 months. Tongue-tie severity (grades four through one, most to least severe, using the functional classification of ankyloglossia based on the tongue range of motion ratio³) were graded as follows: 20.7% grade 4, 61.2% grade 3, 13.3% grade 2 with a posterior restriction, 4.7% grade 1 with a posterior restriction (Fig. 1). Compensation patterns (floor of mouth elevation and muscular neck engagement to compensate for restrictive tongue mobility) that would affect the grading of

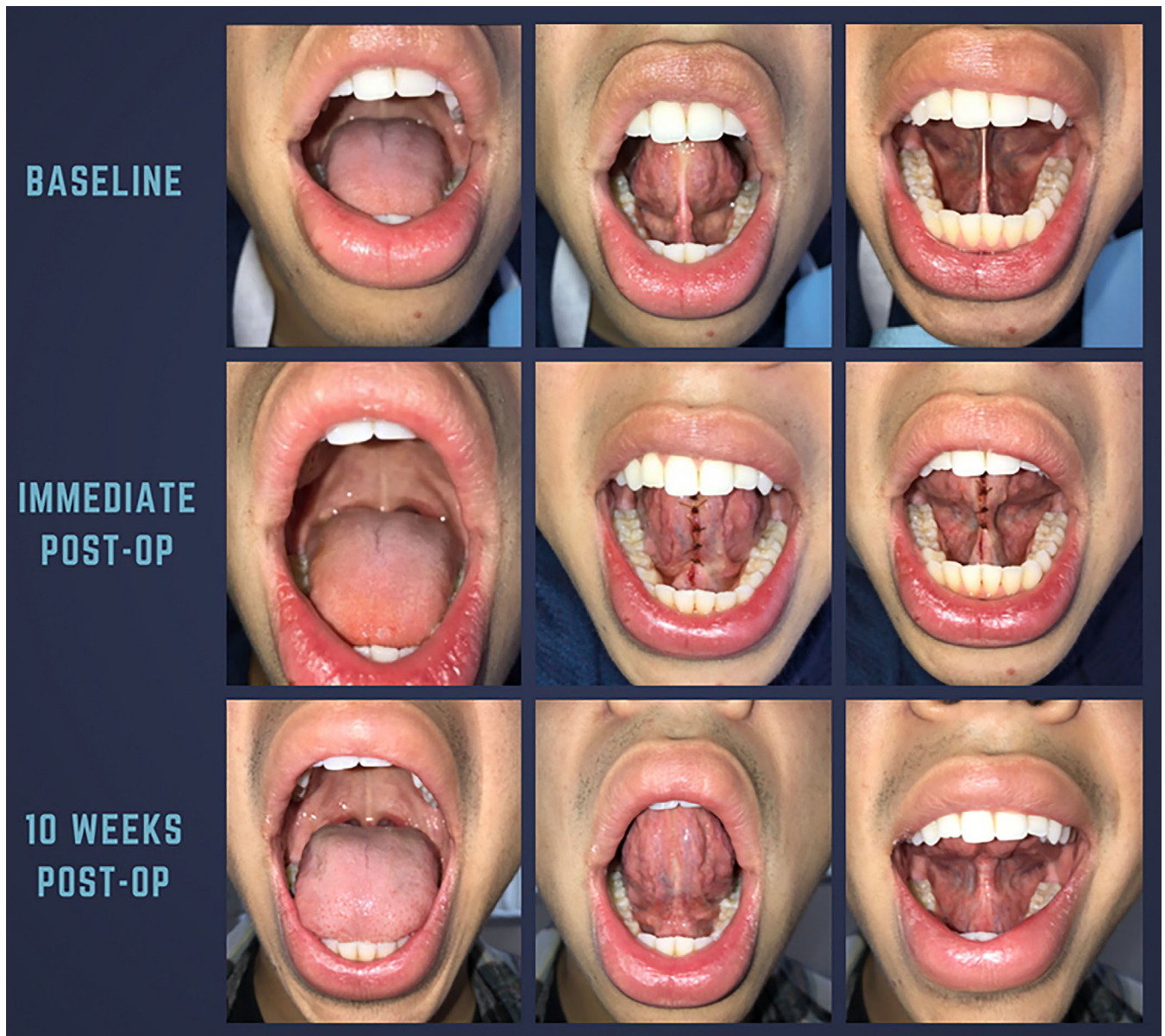

Fig. 1. Case example: 19-year-old man presenting with mumbling, drooling, unrefreshing sleep, fragmented sleep, and chronic mouth breathing associated with grade 3 functional ankyloglossia (<50% mobility of the tongue-tip to the incisive papilla compared to maximal incisal opening). Note the compensation patterns of floor of mouth elevation and tension on the attached gingiva due to the restrictive lingual frenulum. Baseline images obtained after preparation with preoperative myofunctional therapy, immediately prior to surgical release. Immediate postoperative images show excision of the mucosal frenulum and submucosal myofascial fibers with primary intention closure using 4-0 chromic suture. Note the release of tension from the floor of mouth and attached gingiva, as well as the improved tongue mobility. Photos are taken in neutral position, tongue elevated to the central incisors, and while in suction-hold (i.e., lingual-palatal suction, “cave”).

tongue mobility were present and identified in 36.1% of cases (Fig. 2). There were 11.7% ($n = 41$) of patients who had a prior frenectomy elsewhere with persistent restrictions to tongue mobility (Fig. 3).

Benefits

There was an overall satisfaction rate of 91.1% (including 71.8% “very satisfied” and 19.3% “somewhat satisfied”), whereas 6.0% were neutral and 2.9% of patients reported dissatisfaction with the treatment protocol (Table I). Improvement to health-related quality of life was reported

by 87.4% (Table II). Benefits reported by the patients included improvement to tongue mobility ($96.5 \pm 1.0\%$); clenching or grinding of teeth ($91.0 \pm 4.3\%$); ability to perform myofunctional therapy exercises ($89.8 \pm 1.6\%$); ease of swallow ($80.3 \pm 3.5\%$); sleep quality ($79.6 \pm 2.6\%$); nasal breathing ($78.4 \pm 2.8\%$); neck, shoulder, facial tension, or pain ($77.5 \pm 3.4\%$); and snoring ($72.9 \pm 3.4\%$) (Table III).

Complications

There were 45.1% of patients who reported experiencing postoperative pain; average duration of pain was

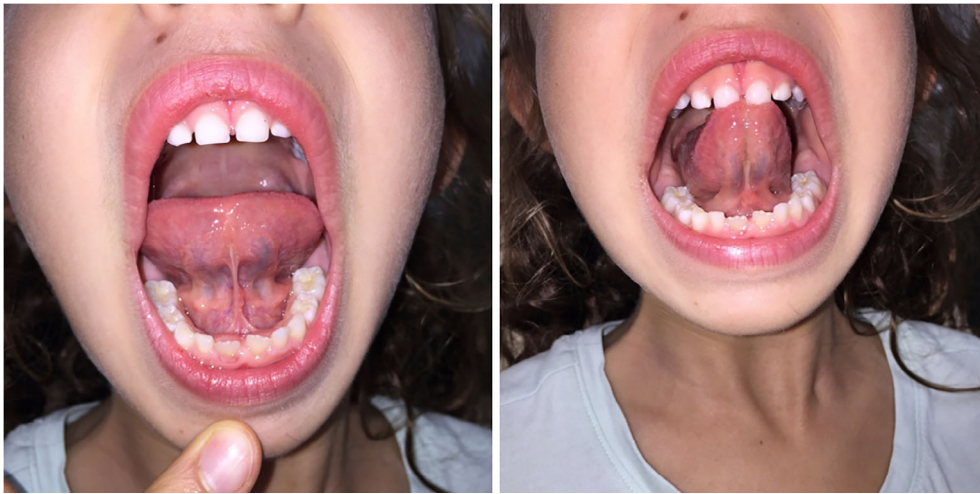

Fig. 2. Case example: 6-year-old girl with restless sleep, nail biting, dental grinding, and open mouth breathing presenting with grade 3 compensating to grade 2 tongue mobility. The image on the left shows <50% mobility (grade 3 TRMR) with floor of mouth elevation and tension on attached gingiva. The image on the right shows 50%–80% mobility (grade 2), however, the patient exerts extensive strain from the floor of mouth and muscular neck to compensate for the restricted tongue mobility.

3.3 ± 2.6 days with severity rating of 6.5 ± 1.9 (VAS: 0–10, mean ± SD). Severity of pain was most highly associated with depth of the surgical dissection and extent to which restrictions of the genioglossus muscle were released. Other factors associated with pain severity include: low tongue tone, less than ideal preoperative myofunctional therapy compliance, prior myofascial pain syndromes, and patient declining to take postoperative pain medications.

Minor surgical site bleeding was reported by 12.6% of patients; most bleeding resolved within the first 3 hours, however there were 2.0% of patients that reported bleeding that lasted between 24 and 48 hours. Numbness of the

tongue-tip was reported by 4.9% of patients; numbness resolved in 47.1% of cases within 2 weeks, 70% within 2 months, and 99.7% within 6 months. One patient reported tongue numbness beyond 1 year. Salivary gland issues were reported by 3.4% of patients; common issues included inflammation and swelling of the submandibular gland ducts, increased salivation, and jetting of saliva when lifting the tongue or eating. Most of these issues self-resolved within 1–2 weeks. There were 3.2% of patients who had worsened mobility after the lingual frenuloplasty who proceeded with a revision procedure to excise restrictive scar tissue; in addition, there were an additional 3.4%

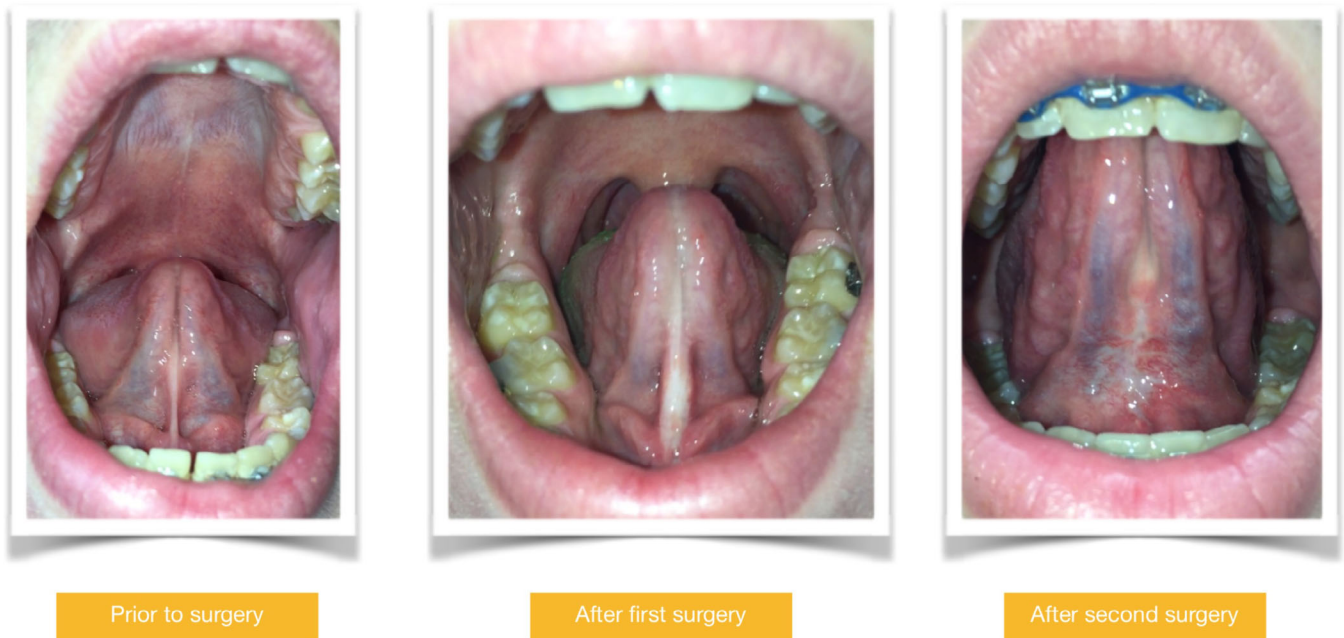


Fig. 3. Case example: 16-year-old boy with grade 4 functional ankyloglossia (<25% TRMR) with persistently restricted tongue mobility (grade 3, <50% TRMR) despite initial laser frenectomy (performed elsewhere) who was rehabilitated to grade 1 mobility (>80% TRMR) with lingual frenuloplasty and myofunctional therapy protocol.

TABLE I.
Patient-Reported Satisfaction with Lingual Frenuloplasty and Myofunctional Therapy Treatment Protocol.

Satisfaction	Number	Percent Total	
A (very satisfied)	250	71.8%	Overall satisfied: 91.1%
B (somewhat satisfied)	67	19.3%	
C (neutral)	21	6.0%	
D (somewhat dissatisfied)	10	2.9%	Overall dissatisfied: 2.9%
F (very dissatisfied)	0	0.0%	

TABLE II.
Health-Related Quality of Life (QOL) Following Lingual Frenuloplasty and Myofunctional Therapy Treatment Protocol.

Health-Related Quality of Life	Number	Percent Total	
A (much better)	137	39.3%	Overall QOL improved: 87.4%
B (somewhat better)	167	48.0%	
C (neutral)	42	12.1%	
D (somewhat worse)	2	0.6%	Overall QOL worse: 0.6%
F (much worse)	0	0.0%	

of patients who experienced some initial improvement with a first procedure but then elected to proceed with a second-stage frenuloplasty to further improve tongue mobility. There were three patients who had a third-stage frenuloplasty; in these cases, the wound was left open to healing by secondary intention with good resolution as there was concern these patients may have had inflammation sensitivities to the suture material used for primary intention closure (Table IV).

Two patients reported worsened health symptoms after the procedure (0.6%) that were not associated with scar or wound healing issues; one of these patients was a patient with a narrow posterior airway space for whom measures of sleep-disordered breathing exacerbated after the procedure (Fig. 4). The other was a patient with narrow maxillary width and dental crowding treated for indication of mouth breathing who developed improved tongue resting posture and nasal breathing but reported pain from biting

TABLE III.
Benefits Attributed to Lingual Frenuloplasty with Myofunctional Therapy Protocol.

Benefits	Improved	Did Not Improve	Unsure	N/A	Percent Improved	Standard Error
Overall tongue mobility	326	12	10	—	96.5%	1.0%
Clenching or grinding of teeth	40	4	—	304	91.0%	4.3%
Ability to perform myofunctional therapy exercises	307	35	6	—	89.8%	1.6%
Ease of swallow	102	25	3	218	80.3%	3.5%
Sleep quality	195	50	11	92	79.6%	2.6%
Nasal breathing	174	48	4	122	78.4%	2.8%
Neck, shoulder, facial tension, or pain	117	34	—	197	77.5%	3.4%
Snoring	102	38	11	197	72.9%	3.8%

TABLE IV.
Patient Reported Risks and Complications Associated with Lingual Frenuloplasty.

Risks/Complications	Reported	Not Reported	Percent Reported	Standard Error
Pain	157	191	45.1%	2.7%
Pain for longer than 7 d	5	343	1.4%	0.6%
Bleeding	44	304	12.6%	1.8%
Prolonged bleeding >24 hr	7	341	2.0%	0.8%
Numbness of the tongue-tip	17	331	4.9%	1.2%
Numbness >2 wk	9	339	2.6%	0.9%
Salivary gland issues	12	336	3.4%	1.0%
Complaints >2 wk	3	345	0.9%	0.5%
Second-stage release procedure to further improve tongue mobility after initial improvement	12	336	3.4%	1.0%
Revision surgery to excise scarring that resulted in worse mobility than prior to initial release	11	337	3.2%	0.9%

and clenching on the sides of the tongue with severe tongue scalloping due to insufficient tongue space. These patients were directed to maxillary and mandibular skeletal expansion as the next steps in their treatment.

DISCUSSION

Myofunctional therapy was first described in the medical literature by Alfred Paul Rogers in 1918 as an adjunct to orthodontic treatment to improve mandibular growth, nasal breathing, and facial appearance.¹⁵ The foundational concepts he introduced regarding the importance of tongue-to-palate oral resting posture and nasal breathing for maxillofacial development were largely overlooked at that time despite a restatement of the myofunctional concept to the orthodontic community in 1950.¹⁶ Dr. John Mew, an English orthodontist, is credited for popularizing the Tropic Premise,^{17–19} with the basic concept that the development of facial and dental structures is strongly influenced by the posture and function of the associated soft tissues (i.e., lips, tongue, orofacial, and mastication muscles)^{18,20} and fortified by continuous nasal breathing.^{21–24}

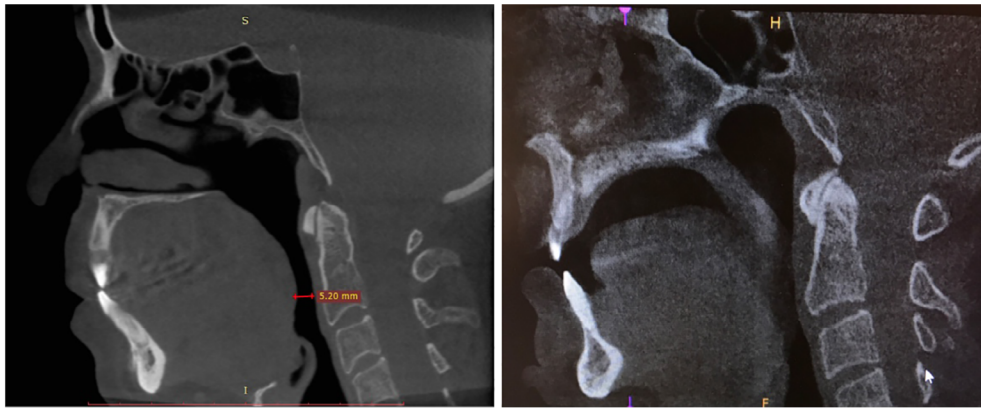


Fig. 4. Use of computed tomography imaging to assess for tongue space in the assessment of candidates for lingual frenuloplasty. The mid-line sagittal image reconstruction of the CT scan is used to assess the available space for the tongue in the oral cavity. Note that despite both patients having similarly restricted amount of posterior airway space, the patient on left has no space between the tongue and the palate (poor candidate), while the patient on the right has a significant amount of space between the tongue and the palate (better candidate). Lingual frenuloplasty and myofunctional therapy are considered to be less effective in patients without adequate oral volume for tongue space. Such patients may be better suited to dental orthopedic remodeling (orthodontics and/or orthognathic surgery for expansion and advancement of the skeletal framework) to increase the tongue space in addition or prior to treatment with lingual frenuloplasty.

Techniques for reeducation of the orofacial muscles were published in French in the 1990s.²⁵ Even so, many thought leaders were slow to adopt these principles citing a lack of randomized control trials²⁶ and high-level evidence-based research.²⁷ Renewed interest for myofunctional therapy was garnered with a series of randomized control trials^{28–30} and cohort studies investigating the role of oropharyngeal exercises, speech therapy, myofascial reeducation,³¹ and oronasal rehabilitation³² for adults and children with sleep-disordered breathing. Furthermore, a more recent series of meta-analysis,^{12,13} review articles,³³ books,^{34–36} commentaries,^{24,37} and position statements³⁸ have catapulted myofunctional therapy to the forefront of the attention within dental and medical communities, albeit not without criticism.

In this setting, there is increased attention to ankyloglossia as a limiting factor for achieving one of the basic goals of myofunctional therapy: restoration or habituation of tongue posture to the roof of the mouth at rest (a.k.a., tongue-to-palate contact, lingual palatal suction). Restrictive lingual frenulum has been identified as a phenotype of obstructive sleep apnea in children^{39,40} and adults,⁴¹ and recent studies on the assessment of functional ankyloglossia have been instrumental in identifying a larger population of patients with restricted tongue mobility.³

A growing number of patients and providers are seeking peer-reviewed evidence-based information for the treatment of ankyloglossia; however, few investigators are publishing articles on this topic.⁴² Most articles that are published on this topic consist of limited case reports and case series^{43,44}; larger cohort studies are available on frenectomy techniques for infants as it relates to breastfeeding⁴⁵; however, there is still limited research relating to treatment of ankyloglossia among children,⁴⁶ adolescents,⁴⁷ and adults.^{9,48} In this manuscript, we provide safety, efficacy, complication, and satisfaction results for the largest cohort of patients treated with lingual frenuloplasty and myofunctional therapy to date. The

benefits attributed to improved oral function, breathing, and release of neck tension are explained by resolution of oromyofascial dysfunction with potential mechanisms of action explored in a recent systematic review.³³

The multidisciplinary treatment protocol combining frenuloplasty with myofunctional therapy as described herein was inspired and adapted from prior works.^{43,44,46,49} However, this cohort study is unique as all patients were required to demonstrate compliance to myofunctional therapy for at least 1 month prior and 2 months after surgical treatment. Moreover, the technique described in this manuscript involves a scissors and suture technique (without the use of laser or cautery) that released mucosal elements of the lingual frenulum but also included release of submucosal fascial and genioglossus myofascial fibers if necessary to optimize tongue mobility.⁵⁰

Whereas many patients reported that the treatment protocol was “life-changing” with often dramatic patient testimonials available online, not all patients experienced similar outcomes. Indeed, many patients did not respond to treatment, and some expressed earnest dissatisfaction. Moreover, it should be emphasized that testimonials are not a scientific result and that long-term studies with objective findings are necessary to corroborate the findings of this preliminary report.

Study Limitations

This is a consecutive cohort study of a large number of patients treated by means of a specific surgical technique by a single surgeon. As with any highly skilled work, the outcome of the work is dependent largely upon the individual skill of provider, and as such, there may be limited external generalizability across techniques and providers. The study was done retrospectively. There is no control group. The patient surveys were not validated. In some cases, significant time had passed between the procedure and the survey with the risk of recall error/bias, response bias, and unintentional acquiescence bias.

CONCLUSION

Lingual frenuloplasty with myofunctional therapy protocol as described in this manuscript is a safe and potentially effective treatment for mouth breathing, snoring, clenching, and myofascial tension in appropriately selected patient candidates. Further research will help to better identify the most optimal candidates for this treatment.

ACKNOWLEDGMENT

The authors would like to acknowledge the contributions of Chad Knutsen, Jennifer Rodriguez, William Belshe, Maryam Norouz, Katie Romero, Shahryar Barzegar, Debbie Hang, and Nora Ghodousi-Zaghi for their collaboration in development of this manuscript.

BIBLIOGRAPHY

1. Fernando C. *Tongue Tie—From Confusion to Clarity: A Guide to the Diagnosis and Treatment of Ankyloglossia*. New York, NY, USA: Tandem Publications; 1998.
2. Horton CE, Crawford HH, Adamson JE, Ashbell TS. Tongue-tie. *Cleft Palate J* 1969;6:8–23.
3. Yoon A, Zaghi S, Weitzman R, et al. Toward a functional definition of ankyloglossia: validating current grading scales for lingual frenulum length and tongue mobility in 1052 subjects. *Sleep Breath* 2017;21:767–775.
4. Gross AM, Kellum GD, Hale ST, et al. Myofunctional and dentofacial relationships in second grade children. *Angle Orthod* 1990;60:247–253.
5. Yoon A, Zaghi S, Ha S, Law C, Guilleminault C, Liu S. Ankyloglossia as a risk factor for maxillary hypoplasia and soft palate elongation: a functional–morphological study. *Orthod Craniofac Res* 2017;20:237–244.
6. Stecco C. *Functional Atlas of the Human Fascial System E-Book*. Amsterdam, Netherlands: Elsevier Health Sciences; 2014.
7. Schultz RL, Feitis R. *The Endless Web: Fascial Anatomy and Physical Reality*. Berkeley, CA, USA: North Atlantic Books; 2013.
8. Scoppa F. Glosso-postural syndrome. *Ann Stomatol* 2005;54:27–34.
9. Chinnadurai S, Francis DO, Epstein RA, Morad A, Kohanim S, McPheeters M. Treatment of ankyloglossia for reasons other than breastfeeding: a systematic review. *Pediatrics* 2015;135:e1467–e1474.
10. Hanson ML. Oral myofunctional therapy. *Am J Orthod* 1978;73:56–67.
11. Moeller JL, Paskay LC, Gelb ML. Myofunctional therapy: a novel treatment of pediatric sleep-disordered breathing. *Sleep Med Clin* 2014;9:235–243.
12. Camacho M, Certal V, Abdullatif J, et al. Myofunctional therapy to treat obstructive sleep apnea: a systematic review and meta-analysis. *Sleep* 2015;38:669–675.
13. Camacho M, Guilleminault C, Wei JM, et al. Oropharyngeal and tongue exercises (myofunctional therapy) for snoring: a systematic review and meta-analysis. *Eur Arch Otorhinolaryngol* 2018;275:849–855.
14. Moeller MR. The emerging area of orofacial myofunctional therapy: Efficacy of treatment in sleep disordered breathing bringing promise of a new field of medicine. *Cranio* 2018;36:283–285.
15. Rogers AP. Muscle training and its relation to orthodontia. *Int J Orthod* 1918;4:555–577.
16. Rogers AP. A restatement of the myofunctional concept in orthodontics. *Am J Orthod* 1950;36:845–855.
17. Mew J. The aetiology of malocclusion. Can the tropic premise assist our understanding? *Br Dent J* 1981;151:296.
18. Mew J. Tongue posture. *Br J Orthod* 1981;8:203–211.
19. Mew JR. The postural basis of malocclusion: a philosophical overview. *Am J Orthod Dentofac Orthop* 2004;126:729–738.
20. Harvold EP, Chierici G, Vargervik K. Experiments on the development of dental malocclusions. *Am J Orthod* 1972;61:38–44.
21. Harvold EP, Tomer BS, Vargervik K, Chierici G. Primate experiments on oral respiration. *Am J Orthod* 1981;79:359–372.
22. McNamara JA Jr. Influence of respiratory pattern on craniofacial growth. *Angle Orthod* 1981;51:269–300.
23. Grippaudo C, Paolantonio E, Antonini G, Saule R, La Torre G, Deli R. Association between oral habits, mouth breathing and malocclusion. *Acta Otorhinolaryngol Ital* 2016;36:386.
24. Torre C, Guilleminault C. Establishment of nasal breathing should be the ultimate goal to secure adequate craniofacial and airway development in children. *J Pediatr* 2018;94:101–103.
25. Chauvois A, Fournier M, Girardin F. *Rééducation des fonctions dans la thérapie orthodontique*. Paris, France: SID; 1991.
26. Mew J. Are random controlled trials appropriate for orthodontics? *Evid Base Dent* 2002;3:35.
27. Mew JR. Does “evidence-based research” provide needed evidence? *Am J Orthod Dentofac Orthop* 2004;125:A20.
28. Guimaraes KC, Drager LF, Genta PR, Marcondes BF, Lorenzi-Filho G. Effects of oropharyngeal exercises on patients with moderate obstructive sleep apnea syndrome. *Am J Respir Crit Care Med* 2009;179:962–966.
29. Diaferia G, Badke L, Santos-Silva R, Bommarito S, Tufik S, Bittencourt L. Effect of speech therapy as adjunct treatment to continuous positive airway pressure on the quality of life of patients with obstructive sleep apnea. *Sleep Med* 2013;14:628–635.
30. Villa MP, Brasili L, Ferretti A, et al. Oropharyngeal exercises to reduce symptoms of OSA after AT. *Sleep Breath* 2015;19:281–289.
31. Guilleminault C, Huang Y, Monteyrol P, Sato R, Quo S, Lin C. Critical role of myofascial reeducation in pediatric sleep-disordered breathing. *Sleep Med* 2013;14:518–525.
32. Levrini L, Lorusso P, Caprioglio A, et al. Model of oronasal rehabilitation in children with obstructive sleep apnea syndrome undergoing rapid maxillary expansion: research review. *Sleep Sci* 2014;7:225–233.
33. de Felício CM, da Silva Dias FV, Trawitzki LVV. Obstructive sleep apnea: focus on myofunctional therapy. *Nat Sci Sleep* 2018;10:271.
34. Gelb M, Hindin H. *Gasp: Airway Health: The Hidden Path to Wellness*. New York, NY, USA: CreateSpace Independent Publishing Platform; 2016.
35. Liao F. *Six-Foot Tiger, Three-Foot Cage: Take Charge of Your Health by Taking Charge of Your Mouth*. Carlsbad, CA, USA: Crescendo Publishing LLC; 2017.
36. Kahn S, Ehrlich PR. *Jaws: The Story of a Hidden Epidemic*. Palo Alto, CA: Stanford University Press; 2018.
37. Guilleminault C, Sullivan S. Towards restoration of continuous nasal breathing as the ultimate treatment goal in pediatric obstructive sleep apnea. *Enliven: Pediatr Neonatol Biol* 2014;1:001.
38. Burger D. Pediatric airway symposium to clear the air on dental screening, treatment. *ADA News*. <https://www.ada.org/en/publications/ada-news/2018-archive/june/pediatric-airway-symposium-to-clear-the-air-on-dental-screening-treatment>. American Dental Association, 2018.
39. Guilleminault C, Huseni S, Lo L. A frequent phenotype for paediatric sleep apnoea: short lingual frenulum. *ERJ Open Res* 2016;2:00043–02016.
40. Huang Y, Quo S, Berkowski J, Guilleminault C. Short lingual frenulum and obstructive sleep apnea in children. *Int J Pediatr Res* 2015;1:1–4.
41. Chien Y, Guilleminault C. Adult short lingual frenulum and obstructive sleep apnea. *J Sleep Sleep Disorders Res* 2017;40:A164–A165.
42. Aaronson NL, Castaño JE, Simons JP, Jabbour N. Quality, readability, and trends for websites on ankyloglossia. *Ann Otol Rhinol Laryngol* 2018;127:439–444.
43. Tsaousoglou P, Popouzelis N, Vouros I, Sculean A. Diagnosis and treatment of ankyloglossia: a narrative review and a report of three cases. *Quintessence Int* 2016;47:523–534.
44. Junqueira MA, Cunha NNO, e SILVA C, et al. Surgical techniques for the treatment of ankyloglossia in children: a case series. *J Appl Oral Sci* 2014;22:241–248.
45. Ghaheri BA, Cole M, Fausel SC, Chuop M, Mace JC. Breastfeeding improvement following tongue-tie and lip-tie release: a prospective cohort study. *Laryngoscope* 2017;127:1217–1223.
46. Ferrés-Amat E, Pastor-Vera T, Ferrés-Amat E, Mareque-Bueno J, Prats-Armengol J, Ferrés-Padró E. Multidisciplinary management of ankyloglossia in childhood. Treatment of 101 cases. A protocol. *Med Oral Patol Oral Cir Bucal* 2016;21:e39.
47. Lalakea ML, Messner AH. Ankyloglossia: the adolescent and adult perspective. *Otolaryngol Head Neck Surg* 2003;128:746–752.
48. Lalakea ML, Messner AH. Ankyloglossia: does it matter? *Pediatr Clin North Am* 2003;50:381–397.
49. Fabbie P, Kundel L, Vitruk P. Tongue-tie functional release. *Dent Sleep Practice Winter* 2016;40–45. Available at: <https://dentalsleeppractice.com/articles/tongue-tie-functional-release/>
50. Mills N, Pransky SM, Geddes DT, Mirjalili SA. What is a tongue tie? Defining the anatomy of the in-situ lingual frenulum. *Clin Anat* 2019. Available at: <https://onlinelibrary.wiley.com/doi/10.1002/ca.23343>